

Scientific review

## SURFER'S MYELOPATHY - NEW CLINICAL ENTITY

UDK 616.832:797.178

**Ružica Conić<sup>1</sup>**

Belgrade University, School of Medicine, Serbia

---

**Abstract:** Surfer's myelopathy is a clinical entity first described in 2004. It is non-traumatic spinal cord damage that occurs due to hyperextension of the lumbar part of the spinal column in certain phases of surfing, and almost exclusively affects beginners. Ischemic changes in the spinal cord, venous thrombosis and fibro-cartilaginous embolism are considered the possible causes. Although relatively rare, in over 50% of the cases it has serious consequences in the form of a permanent paralysis of lower extremities, bladder and bowel dysfunction.

Magnetic resonance imaging, lab analysis and cerebrospinal fluid analysis are used for diagnostics and to exclude other disorders which could result in paraplegia. Therapeutically, corticosteroids are administered to decrease swelling of the spinal cord, and rehydration is used to recover circulating fluid volume. Rehabilitation includes procedures that are used in other lesions of the spinal cord resulting in paraplegia. The possibility for full recovery mostly depends on the extent of initial neurologic deficit.

Possible prevention implies paravertebral muscle strengthening and exercises for improving body balance. In any sport or activity where spinal column hyperextension occurs, cessation of practicing the sport is recommended if it is causing back pain, in order to prevent further injury and evaluate the possible etiology of pain.

**Key words:** *non-traumatic myelopathy, spinal cord, back pain, surfing*

---

---

1   ✉ [ruzica.conic@gmail.com](mailto:ruzica.conic@gmail.com)

## INTRODUCTION

Playing sports carries a risk of injuries. Some injuries occur due to repetitive movements and are characteristic for certain sports, such as tennis elbow, golfer's elbow, swimmer's shoulder, runner's knee, etc. These injuries are usually called sports injuries. On the other hand, sudden movements, falls, collisions or physical contact in combat sports, can lead to trauma varying from minor contusions which heal without treatment to serious injuries of the locomotor, central nervous system and internal organs that may result in serious disability or even death. These injuries are not characteristic for sports, but may happen in everyday life, like for example in traffic accidents. If occurring during sports activities, they are usually called injuries in sports.

Since sports activities and competitions have existed for thousands of years, the knowledge about the types of injuries that might occur has accumulated. Due to advances of medical diagnostics, especially computerized tomography (CT) and magnetic resonance imaging (MRI), there has been an increase in injury diagnostics precision, especially for soft tissue injuries. The efficiency of treatment has also improved for both the operative and conservative approaches.

The mechanism of sports injury occurrence, their pathological characteristics, types of treatment and prevention have undergone a lot of study. Diagnostic and therapeutic protocols have been established and are used routinely. Preventive measures are also well known and routinely recommended. There are almost no unknown elements for sports medicine experts, because of the extent of sports activity participation. Therefore, it is well known how and to what degree a person participating in sports can undergo injury.

## CLINICAL FINDINGS

Surfing does not differ from other sports in the possibility for injuries. Two studies on 1,660 injured surfers show that the most common injuries are lacerations (42%), contusions (13%), strains and sprains (12%), as well as fractures (8%). Injuries of lower extremities and head and neck are equally represented with 37% each (de Moraes et al., 2013). Vertebral fractures are rare, occurring in 0.3%, mostly during the head hitting the sea bottom (Nathanson et al., 2002).

Thompson and associates in 2004 showed that these are not the only injuries that may happen during surfing. They published an analysis of 9 cases of non-traumatic damage to the spinal cord that occurred during surfing, and named it surfer's myelopathy (Thompson et al., 2004). All patients were

primarily admitted as emergency cases in the Straub clinic and a hospital in Honolulu, Hawaii.

The average age in their patient series was 25 years. Patients were mostly male (8 vs. 1), with a lean build, and as a rule beginners in surfing. The damage almost always occurred during the first day of surfing. In one case it occurred on the beach, during demonstration and practicing of take-off on the surf board, before even entering the water.

The problems started in almost the same way in all patients. At first, a back pain of varying intensity would occur. In some patients, the pain started gradually. At first it was a low intensity pain that progressively increased. The others described sharp pain, suddenly appearing while changing the body position on the surf board from prone to kneeling. Some patients in the latter group said it felt like "something had snapped in their back", which resembles the description of pain felt during lumbar disc herniation.

The pain was followed with numbness in the lower extremities (paresthesia) and partial or complete weakness of lower extremities (paraparesis and paraplegia). In some patients a complete sensory loss from the waist down was present, while in others there was a decreased sensitivity to touch and pain in the lower extremities (hypoesthesia) or increased sensitivity (hyperesthesia).

The weakness of the lower extremities and sensory loss were accompanied by a disorder in the bladder function named atonic bladder. The tone of the bladder wall was weak, allowing it to distend and accept larger amounts of urine than usual. There was no urge for urination and if the catheter was not placed to allow the bladder emptying, there was a danger of bladder rupture and spilling of its content into abdominal cavity. In addition there was a decrease of the anal sphincter tone accompanied with the inability to empty the colon.

Complete clinical findings developed rapidly after the first symptoms occurrence, within 15-30 minutes, and in some cases 60 minutes (Chang et al., 2012). After this period, the patients were mostly unable to walk and were hospitalized.

After the first published case series with this new clinical entity there were multiple papers with case reports or studies with the largest having 19 and 23 patients (Chang et al., 2012, Nakamoto et al., 2013). In these publications the clinical picture is almost identical (Fessa and Lee, 2007, Karabegović et al., 2011, Chung et al., 2011, Lieske et al., 2011, Shuster and Franchetto, 2011). The mentioned authors used the term non-traumatic myelopathy, along with surfer's myelopathy.

Although a small number of cases have been reported in literature until now, Thompson and associates in their paper note that they found about the

other similar cases in communication with other medical centers in Hawaii, but the exact number is unknown.

## DIAGNOSTIC FINDINGS

The most useful diagnostic method in surfer's myelopathy is magnetic resonance imaging. This method revealed ischemic changes in the spinal cord in all published cases. Those changes were present in mid and lower thoracic segments, starting from the fifth thoracic segment (Th5), distally to medullar cone (Nakamoto et al., 2013). At the beginning of the disorder, the swelling of the spinal cord was present, and in cases that followed for the longer period of time, consecutive atrophic changes were noticed (Aoki et al., 2013).

None of the patients had degeneration or lumbar disc protrusion, or other pathological changes such as spondylolisthesis, vascular anomalies, tumors or similar diseases that might present itself as lower extremities weakness. Analysis of cerebrospinal fluid did not show signs of bacterial or viral infections, as well as no products indicating demyelinating diseases like multiple sclerosis, or autoimmune diseases.

Diagnosis of new clinical entity- surfer's myelopathy is a diagnosis of systematic and careful exclusion of all other possible causes of paraplegia.

## POSSIBLE CAUSES

The pathophysiological mechanisms of surfer's myelopathy include several possible reasons. At first, it is a spinal cord ischemia due to spasm of supplying arteries, or due to rupture of communicating arteries in the spinal cord, or due to excessive stretching of the spinal cord that occurs in a certain position at the surf board, which will be described later. Other possible causes are venous stasis in spinal veins and venous thrombosis.

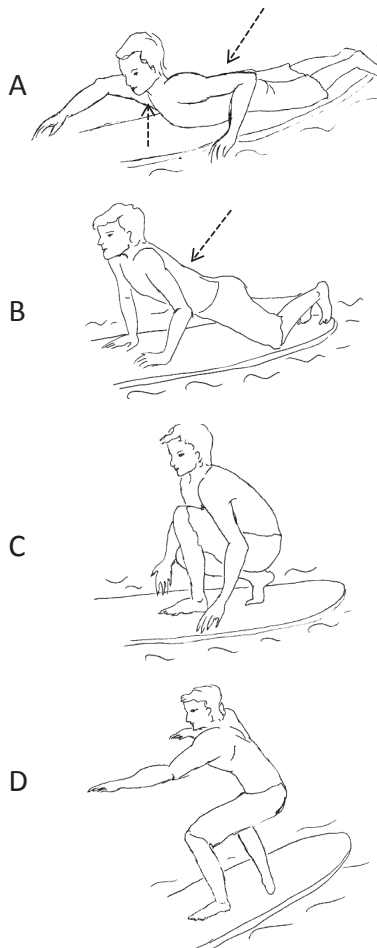
Some authors consider fibro-cartilaginous embolism as a possible cause. It is a clogging of spinal arteries with material from partially liquid part of intervertebral disc (pulpous nucleus). During excessive physical activity, microscopic amounts of nucleus are embedded into the spongy bone of vertebra and its arterial sinuses, and from there they enter spinal arteries and cause an embolism (Han et al., 2004).

The pathological mechanism most often considered to cause surfer's myelopathy is prolonged spinal cord hyperextension (Thompson et al., 2004, Nakamoto et al., 2013).

The sequence of movements that a surfer makes is shown in Picture 1. The surfer lies in a prone position (on his stomach) on the surf board

and paddles to a desired spot. When the wave is coming he pushes against the board to raise his upper body and suddenly changes the position into a squatting with one leg in front (take-off or pop-up), after which he raises himself into a surfing position.

Picture 1. *Position of the body during surfing. A- prone position with raised head and hyperextension of lumbar part of spinal cord (paddling). B and C - taking a squatting position (pop up/take-off) D - straightening into position for surfing.*



The first two positions are considered critical for the occurrence of surfer's myelopathy. While lying on the board and paddling, the head of the surfer is raised from the board and the lumbar part of spinal column is in a hyperextended position. The time that a beginner surfer spends in this position is of key importance. Experienced surfers that don't get injured typically spend very little time in this position - just enough to reach a wave. If they are resting or waiting for a wave they most often sit on the surf board, or more precisely "ride" the surf board. Beginners, however, spend most of their time in the hyperextended position whether they are waiting for a suitable moment to change position, hesitate to pop-up, or are resting (Chang et al., 2012).

The theory that venous thrombosis is the cause of surfer's myelopathy also blames the prone position due to the pressure the surfer puts on the surf board with his abdomen. The pressure carries to the liver and portal blood flow and slows the return of venous blood to the inferior vena cava, causing a block in spinal cord blood flow (Aviles-Hernandez et al., 2007). Venous block is enhanced by dehydration that increases the thickness of the blood, and a possible venous stasis after long flights. Most of the patients were tourists that arrived by long-haul flights right before surfing. The Valsalva manoeuvre which inexperienced surfers do by reflex during paddling is an additional factor in venous stasis. This manoeuvre consists of a deep breath and breathing attempt through closed airways thus increasing intra-abdominal and intramedullary pressure and slowing venous drainage from the spinal cord.

Changing the position into squatting adds to spinal cord ischemia. At first because the lumbar hyperlordosis increases during raising the upper body with stretched arms and because taking the squatting position reflexively causes the Valsalva manoeuvre.

## RECOVERY AND FINAL OUTCOME

Surfer's myelopathy deserves special attention in sports and the medical community not because it is a common occurrence, but because of a possible injury mechanism and a poor clinical outcome - at least in the cases published thus far.

Of 9 patients in Thompson's series, only 3 recovered completely. One remained completely paraplegic, and remaining 5 recovered partially with residual motor, sensory deficit and urinary retention.

Table 1. shows the outcome of single cases published in literature - but the outcomes are worse than in Thompson's series with no one achieving full recovery. Four patients had partial recovery, while the remaining 7 remained permanently wheelchair-bound with complete paraplegia and consecutive urinary bladder and bowel dysfunction.

Table 1. *Clinical outcomes of surfer's myelopathy in single case reports*

AUTHOR, YEAR	COUNTRY IN WHICH THE SYMPTOMS OCCURRED	GENDER, AGE	OUTCOME
Aviles-Hernandez, 2007	USA	male, 37	Paraplegia
Shuster, 2010	USA (Hawaii)	male, 23	Paraplegia
Karabegović, 2010	Indonesia	male, 25	Partial recovery
Chung, 2011	Taiwan	female, 24	Partial recovery
Shuster, 2011	USA (Hawaii)	male, 23	Paraplegia
Lieske, 2011	USA (Virginia)	female, 15	Partial recovery
Fessa, 2012	Australia	male, 19	Paraplegia
Aoki, 2013	Japan	male, 26	Partial recovery
Takakura, 2013	USA (Hawaii) USA (Hawaii) Japan	male, 31 female, 24 male, 25	Paraplegia paraplegia paraplegia

In a study of radiologic findings in 23 patients with surfer's myelopathy, 65% of the patients had no clinical recovery (Nakamoto et al., 2013). However, this study lacks long term follow-up, so the final outcome is uncertain.

In an analysis of 19 patients with surfer's myelopathy, long-term follow-up is also lacking for some of the patients. Patients had a follow-up from 3 days to 3 years after the weakness occurrence (Chang et al., 2012). Even though the group lacked homogeneity, the recovery was better for patients with less pronounced initial motor weakness. Ten patients from this group (52%) had severe motor and sensory loss, and during follow up, their recovery - if any - was minimal. For patients with incomplete paraplegia, the recovery of various degrees was established.

Neurological deficits on admission were a better predictor of recovery than MRI findings (Chang et al., 2012, Nakamoto et al., 2013). The American Spinal Injury Association (ASIA) score that grades motor and sensory deficits after injury from A to E, with A being the worst possibly, has equal or even higher significance for recovery than MRI findings (Marino et al., 2003).

Analysis of these cases of surfer's myelopathy shows that the surfers who continued surfing past the first symptoms of back pain had worse or no recovery than those who stopped. The surfers who stopped when back pain appeared had complete or at least partial recovery.

## TREATMENT

Since the ischemic event is considered the main cause of surfer's myelopathy, Thompson and associates proposed a treatment protocol that includes the administration of steroids as a first step, in order to diminish spinal cord swelling. Rehydration is a parallel measure, which should increase the amount of circulating fluid and decrease the possibility of thrombosis due to hemoconcentration, and raise the blood pressure, thus improving the blood flow to spinal cord.

Rehabilitation measures that follow the principles of paraplegic patient treatment are applied immediately after the damage occurrence. They depend on motor and sensory loss and on the bladder and bowel function as well. In cases where improvement is achieved, the next step is gait education with or without crutches and canes. If the motor and sensory functions do not recover, patient is trained to live with limitations of his motor deficits (use of wheelchair, transfer from bed to wheelchair and vice versa, activities of daily living).

If the bladder and bowel function do not improve, the patient is trained how to empty the bladder and colon by himself (catheter and enema).

## PREVENTION

A well-known fact is that sports activities require preparation, especially in the sports with high physical demand. Lack of preparation either in the form of a complete absence of physical form, poor conditioning or inadequate warming and/or stretching before the physical activity, is a common cause of injuries.

To the theoretical question - is there a possible prevention of surfer's myelopathy - the answer is definitely affirmative. The very knowledge of the possibility of injury and the seriousness of it is sufficient to start this activity prepared, as in other sports. Persons planning to surf, especially those with lean a build, should pay special attention not only to back muscle strengthening, but to abdominal wall muscle strengthening as well. In other words, the strengthening of the entire muscle girdle that supports the spinal column is necessary. The exercises that are routinely performed in persons with degenerative spinal column diseases and lumbar disc herniation could be applied for surfer's myelopathy prevention as well. Muscle strengthening cannot be accomplished in a short period of time, thus exercises should start early.

The maintenance of balance in a sitting position on the surf board is another possible preventive measure because it decreases the amount of time spent in a prone position. Balance exercises with a ball are the simplest way to improve balance.



Among the sports activities that could be suitable for surfing preparation and surfer's myelopathy prevention, swimming surely deserves the leading position. A body submerged in water is lighter due to buoyancy and Archimedes' law. Water offers resistance in movements, so moving through water not only strengthens the muscles, but prevents injuries. Sudden movements that are possible on land are almost impossible to do in water as a medium. Among the swimming techniques, back stroke is the best for paravertebral muscle strengthening.

Serbia does not offer ways to practice surfing, but this does not mean that the possibility for surfer's myelopathy should be ignored. The fact that a prolonged hyperextended position of the spinal column could cause spinal cord ischemia deserves the attention of both physicians and sports trainers. There are other described cases in medical literature where the prolonged hyperextended position of the spinal column caused ischemic damage of spinal cord (Roberts et al., 2003). Therefore, in any sports activity where this position is taken, such as gymnastics, the strengthening of those muscle groups should be useful - to prevent possible ischemic lesions of spinal cord, and prevent lumbar disc hernia. This is especially important for beginners with weak paravertebral muscles.

## **SIGNIFICANCE OF SURFER'S MYELOPATHY FOR CLINICAL AND SPORTS PRACTICE**

Even though the medical term for surfer's myelopathy is non-traumatic myelopathy, it deserves to be added as the new entity to the long list of known sports injuries, because it is closely connected to one particular sport. Unlike tennis elbow, swimmer's shoulder, runner's knee and similar injuries, it is not caused by repetitive movements, but by a certain position of the body that occurs during one specific sport.

An analysis of all presented cases brings even more questions. How many cases of this syndrome remain undiagnosed? How many times was this injury mistaken for lumbar herniated disc? Can a similar injury appear during other sports? The first and second questions are hard to respond to precisely because only the worst cases of motor weakness end up in the hospital. The logical assumption is there are others, with a less pronounced clinical picture, incomplete clinical picture (for example with back pain only), who recover spontaneously or with minimal treatment.

Back pain and disc herniation are common occurrence in athletes. If the diagnostics is not complete (CT or MRI), the cause of pain cannot be accurately determined. Among the cases of surfer's myelopathy presented in literature, special attention should be drawn to the ones that had a sudden onset of back pain, or feeling that something snapped in their back, after

which they felt numbness and weakness in lower extremities, which is typical for lumbar disc herniation. Because of that, it is safe to assume that at least some of the less pronounced cases of surfer's myelopathy have been mistaken for lumbar disc herniation.

Performing CT and MRI for each case of back pain is not possible and not economically justifiable either. Especially if the patient's symptoms are relieved after the standard application of rest, anti-inflammatory and anti-rheumatic drugs, and eventually physical therapy and exercise therapy. Because of this, the logical assumption is that there are significantly more cases of surfer's myelopathy that occurred during other sports where the hyperextended back position is common, but with a less pronounced clinical picture and no permanent consequences, and thus remained undiagnosed.

Whether the new medical knowledge on this rare disorder will give us more detailed insight into its etiology, or remain at the level of academic discussion, we learned several important facts from various sources of literature. First, that a very serious injury can occur during sport activities, with a possible catastrophic outcome for the person playing sports. Thus, to prevent such injuries, education is the first step for both trainer and athlete. Secondly, that every sports activity, both recreational and professional, requires adequate preparation. Preparation is not the "necessary evil" that should be skipped whenever possible, but an important step in injury prevention.

Finally, some symptoms occurring during sports activities might be a signal of more serious disorders, and should not be ignored and written off as intensive training, exhaustion due to back to back competitions, and so on. A timely discontinuation of activity that provokes pain presents the first step towards recovery. It is well known from medical and sports practice that the injuries most resistant to therapy are those with missed opportunity of therapeutic intervention in the earliest phase. An athlete who continues physical activity despite pain, additionally injures the already injured region. If the tissue trauma is big, there is less chance for it to heal without chronic inflammation, calcifications or scar tissue, which all affects the functional capability of the injured region.

In this case, of key importance is the role of a qualified and educated physical therapist who can, during training or competition, evaluate which athletes can continue physical activity, and who should have a doctor's consultation and further tests.

## REFERENCES

1. Aoki, M., Moriizumi, S., Toki, M., Murakami, T. & Ishiai, S. (2013). Rehabilitation and long-term course of non-traumatic myelopathy associated with surfing. *Am J Phys Med Rehabil* 92 (9), 828-832.
2. Aviles-Hernandez, I., Garcia-Zozaya, I. & DeVillasante, J.M. (2007). Nontraumatic myelopathy associated with surfing. *J Spinal Cord Med* 30 (3), 288-293.
3. Chang, C.W., Donovan, D.J., Liem, L.K., O'Phelan, K.H., Green, D.M., Bassin, S. & Asai, S. (2012). Surfer's myelopathy: a case series of 19 novice surfers with nontraumatic myelopathy. *Neurology* 79 (22), 2171-2176.
4. Chung, H.Y., Sun, S.F., Wang, J.L., Lai, P.H. & Hwang, C.W. (2011). Non-traumatic anterior spinal cord infarction in a novice surfer: a case report. *J Neurol Sci* 302 (1-2), 118-120.
5. De Moraes, G.C., Guimaraes, A.T. & Gomes, A.R. (2013). Analysis of injuries' prevalence in surfers from Parana seacoast. *Acta Ortop Bras* 21 (4), 213-218.
6. Fessa, C.K. & Lee, B.S. (2007). An Australian case of surfer's myelopathy. *Clin J Sport Med* 22 (3), 281-283.
7. Han, J.J., Massagli, T.L. & Jaffe, K.M. (2004). Fibrocartilaginous embolism-an uncommon cause of spinal cord infarction: a case report and review of the literature. *Arch Phys Med Rehabil* 85 (1), 153-157.
8. Karabegovic, A., Strachan-Jackman, S. & Carr, D. (2011). Surfer's myelopathy: case report and review. *Cjem* 13 (5), 357-360.
9. Lieske, J., Cameron, B., Drinkwine, B., Goretzke, S., Alemi, L., Needham, K., Ventura, J., Ho, V.T. & La Barge, D.V., 3rd. (2011). Surfer's myelopathy-demonstrated by diffusion-weighted magnetic resonance imaging: a case report and literature review. *J Comput Assist Tomogr* 35 (4), 492-494.
10. Marino, R.J., Barros, T., Biering-Sorensen, F., Burns, S.P., Donovan, W.H., Graves, D.E., Haak, M., Hudson, L.M. & Priebe, M.M. (2003). International standards for neurological classification of spinal cord injury. *J Spinal Cord Med* 26 Suppl 1, S50-56.
11. Nakamoto, B.K., Siu, A.M., Hashiba, K.A., Sinclair, B.T., Baker, B.J., Gerber, M.S., McMurtray, A.M., Pearce, A.M. & Pearce, J.W. (2013). Surfer's myelopathy: a radiologic study of 23 cases. *AJNR Am J Neuroradiol* 34 (12), 2393-2398.
12. Nathanson, A., Haynes, P. & Galanis, D. (2002). Surfing injuries. *Am J Emerg Med* 20 (3), 155-160.
13. Roberts, D.R., Roe, J. & Boudouin, C. (2003). Hyperlordosis as a possible factor in the development of spinal cord infarction. *Br J Anaesth* 90 (6), 797-800.

14. Shuster, A. & Franchetto, A. (2011). Surfer's myelopathy-an unusual cause of acute spinal cord ischemia: a case report and review of the literature. *Emerg Radiol* 18 (1), 57-60.
15. Thompson, T.P., Pearce, J., Chang, G. & Madamba, J. (2004). Surfer's myelopathy. *Spine (Phila Pa 1976)* 29 (16), E353-356.